

Research Article

Inhibition of EGFR-STAT3 Signaling with Erlotinib Prevents Carcinogenesis in a Chemically-Induced Mouse Model of Oral Squamous Cell Carcinoma

Rebecca J. Leeman-Neill¹, Raja R. Seethala¹, Shivendra V. Singh², Maria L. Freilino³, Joseph S. Bednash³, Sufi M. Thomas³, Mary C. Panahandeh³, William E. Gooding⁴, Sonali C. Joyce³, Mark W. Lingen⁶, Daniel B. Neill⁵, and Jennifer R. Grandis^{1,2,3}

Abstract

Chemoprevention of head and neck squamous cell carcinoma (HNSCC), a disease associated with high mortality rates and frequent occurrence of second primary tumor (SPT), is an important clinical goal. The epidermal growth factor receptor (EGFR)-signal transducer and activator of transcription (STAT)-3 signaling pathway is known to play a key role in HNSCC growth, survival, and prognosis, thereby serving as a potential therapeutic target in the treatment of HNSCC. In the current study, the 4-nitroquinoline-1-oxide (4-NQO)-induced murine model of oral carcinogenesis was utilized to investigate the chemopreventive activities of compounds that target the EGFR-STAT3 signaling pathway. This model mimics the process of oral carcinogenesis in humans. The drugs under investigation included erlotinib, a small molecule inhibitor of the EGFR, and guggulipid, the extract of an Ayurvedic medicinal plant, which contains guggulsterone, a compound known to inhibit STAT3. Dietary administration of guggulipid failed to confer protection against oral carcinogenesis. On the other hand, the mice placed on erlotinib-supplemented diet exhibited a 69% decrease ($P < 0.001$) in incidence of preneoplastic and neoplastic lesions compared with mice on the control diet. Immunostaining of dysplastic lesions demonstrated modest decreases in STAT3 levels, with both drug treatments, that were not statistically significant. The results of the present study provide the basis for exploring the efficacy of erlotinib for prevention of HNSCC in a clinical setting. *Cancer Prev Res*; 4(2); 230–7. ©2010 AACR.

Introduction

Head and neck squamous cell carcinoma (HNSCC) is a devastating disease associated with a mortality rate of approximately 50% that has not changed for several decades (1). In addition to high rates of recurrence, HNSCC is associated with frequent formation of second primary tumor (SPT), in 3% to 7% per year, among the highest for any malignancy (2). The high rate of SPT has been attributed to the occurrence of "field cancerization," a term coined by Slaughter and colleagues to define global molecular changes to the upper airway mucosa upon exposure to carcinogens (3). HNSCC, therefore, is a particularly

appropriate target for chemoprevention. Chemopreventive agents may serve as appropriate therapy for patients with a premalignant lesion or patients who have had HNSCC and are at high risk for recurrence and/or SPT. If the agent is safe and devoid of major side effects, it may also be considered for use in primary prevention of HNSCC.

On the basis of early observations that tumors of the upper aerodigestive tract and lungs occurred more frequently in cattle who were deficient in vitamin A (4), studies investigating high-dose retinoids as chemopreventive therapy for HNSCC demonstrated efficacy in delaying carcinogenesis in humans but were associated with considerable toxicity (5, 6). Since then, definitive trials involving administration of tolerable doses of retinoids have not consistently demonstrated prevention of HNSCC (7, 8). The need for identification of novel approaches to prevent HNSCC has become apparent. Recent clinical trials demonstrating chemoprevention of HNSCC have employed green tea (9–11) and Bowman-Birk inhibitor derived from soybeans (12). Studies investigating potential roles for COX-2 and epidermal growth factor receptor (EGFR) inhibition in HNSCC chemoprevention are also currently underway (13). Other compounds that have demonstrated efficacy in preventing carcinogenesis in the preclinical model of

Authors' Affiliations: Departments of ¹Pathology, ²Pharmacology, ³Otolaryngology, and ⁴Biostatistics, University of Pittsburgh and University of Pittsburgh Cancer Institute; ⁵H.J. Heinz III College, Carnegie Mellon University, Pittsburgh, Pennsylvania; and ⁶Department of Pathology, University of Chicago, Chicago, Illinois

Corresponding Author: Jennifer R. Grandis, 200 Lothrop St., Eye and Ear Institute, Suite 500, Pittsburgh, Pennsylvania. Phone: 412-647-5280; Fax: 412-383-5409. E-mail: grandisjr@upmc.edu

doi: 10.1158/1940-6207.CAPR-10-0249

©2010 American Association for Cancer Research.

carcinogenesis used in the current study include rapamycin (14) and ABT-510, an inhibitor of angiogenesis (15).

In the current study, we focused on targeting the EGFR-STAT3 signaling pathway. EGFR, one of the ErbB family of receptors, which is overexpressed in over 80% of HNSCC tumors, is a marker of poor prognosis in patients with HNSCC (16). A recent study has found that EGFR gene copy number can be used to predict progression from oral premalignant lesions to oral squamous cell carcinoma (17). Erlotinib (Tarceva) is an EGFR-targeting tyrosine kinase inhibitor (TKI) that has shown promise in clinical trials with HNSCC and is currently in advanced stages of clinical testing for treatment of this disease. The chemopreventive activity of the EGFR inhibitor, gefitinib, has recently been demonstrated in an animal model of lung cancer (18). Similar observations in an animal model of HNSCC would provide further preclinical basis for ongoing clinical trials investigating EGFR-inhibiting agents as chemopreventive therapy in HNSCC (19–21). STAT3 mediates signaling through the EGFR, regulating the expression of genes that control the cell cycle, and apoptosis (22). STAT3 is constitutively active in the majority of HNSCC tumors where it has been found to play an important role in growth and survival in preclinical models of HNSCC as well as in cellular transformation (23). Various agents that have STAT3 inhibitory properties have been studied for their potential use in treatment of HNSCC, though none have been approved for clinical use (22). Guggulipid is a natural product extracted from the *Commiphora mukul* plant and containing guggulsterone, a compound with a steroid-like structure (24). This compound has been found to have anticancer activity in various preclinical models (25), decreases levels of STAT3 in HNSCC cell lines and tumor xenografts, inhibits tumor growth, and enhances the antitumor activity of EGFR-targeted therapy (26). Furthermore, guggulsterone's safety in clinical trials (27) and availability in inexpensive clinical formulations, such as guggulipid (Sabinsa Corporation), makes it a plausible candidate for use in chemoprevention.

The myriad challenges and costs associated with clinical trials of chemopreventive agents underscore the importance of preclinical studies to provide a biological rationale for use of a given agent as chemopreventive therapy. Although *in vitro* studies can be important in identifying molecular alterations involved in carcinogenesis that can be targeted by a specific agent, true preclinical evidence of cancer prevention, however, requires *in vivo* investigation using a model that recapitulates the process of carcinogenesis in humans. 4-nitroquinoline-1-oxide (4-NQO) is a carcinogen that induces formation of DNA adducts. Oral administration of 4-NQO to mice has been shown to result in the formation of dysplastic lesions and, eventually, neoplasia (28). In addition, the resulting oral squamous cell carcinomas have been found to resemble human HNSCC both histologically and in terms of molecular changes that often characterize human HNSCCs, including changes in levels of EGFR and the cell-cycle regulator p16 (29). This carcinogen has been used to induce HNSCC in

rats and mice, through topical application. More recently, optimal tumor formation has been attained through administration in the animals' drinking water (29).

In the current study, we investigated the chemopreventive properties of both the EGFR-targeting agent, erlotinib, and a natural product with STAT3 inhibitory activity, guggulipid, using the 4-NQO-induced mouse model of oral carcinogenesis. We found that, whereas guggulipid was not effective in inhibiting oral carcinogenesis, erlotinib decreased formation of oral dysplastic lesions.

Materials and Methods

Reagents and animal diets

4-NQO (Sigma Chemical) was dissolved in 100% DMSO (final concentration 50 mg/mL) and kept at -20°C . Guggulipid [solid, 2.65% guggulsterones by high-performance liquid chromatography (HPLC)] was generously provided by Sabinsa Corporation and erlotinib by OSI Pharmaceuticals. Custom erlotinib-supplemented (300 mg/kg) and guggulipid-supplemented diets (28.3 g/kg, equivalent of 750 mg/kg of guggulsterone) were prepared by Harlan Teklad, as an 18% protein rodent diet. Assuming diet consumption of 3 g/mouse/d (based on prior studies; data not shown) and average mouse weight of 22.5 g, mice received approximately 3.77 g/kg of guggulipid (equivalent to 100 mg/kg guggulsterone) or 40 mg/kg of erlotinib per day. Diets were stored in vacuum-sealed bags at 4°C .

Study design and statistics

The study was designed to detect a 25% or greater difference in incidence of preneoplastic and neoplastic lesions in the treated mice versus controls with a power of 0.85. This design required 75 mice per group, relying on the presence of dysplastic or neoplastic lesions in at least 80% of the control group at the end of the experiment. On the basis of prior studies, in which approximately 5% of mice were expected to die from 4-NQO toxicity (data not shown), 80 mice were used per treatment group. In addition, because the kinetics of the 4-NQO model had not been conclusively determined, an adaptive study design was employed. Fifty extra mice were added to the control group so that 10 each could be sacrificed at various time points. If 10 of 10 mice had preneoplastic or neoplastic lesions, there was a probability of 0.89 that at least 80% of the remaining mice in the control group should have lesions as well. The incidences of lesions in the treatment groups were compared using a 2-sided Fisher's exact test.

In immunohistochemistry (IHC) studies, quantitative scores (described later in the text) were assigned to each histologic section and groups compared using a Wilcoxon test.

Animal treatments

Female CBA/J mice (5–6 weeks; Jackson Laboratories) were treated with either the control diet or one of the drug-containing diets for 2 weeks prior to initiating 4-NQO

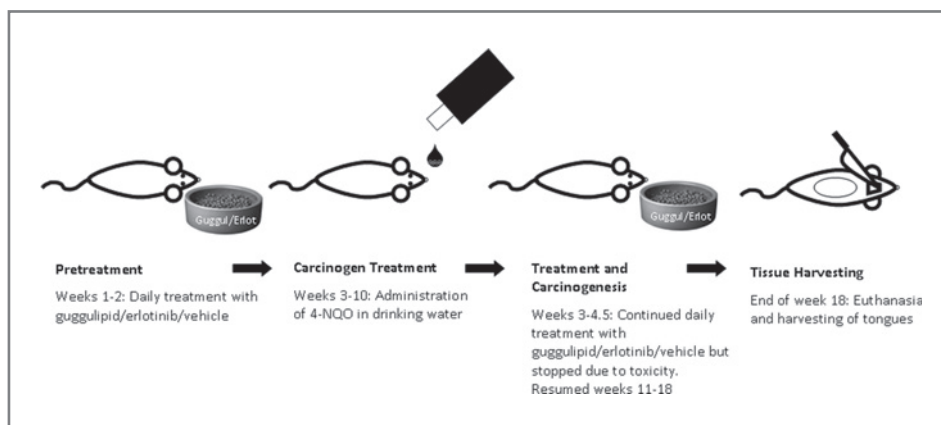


Figure 1. Timeline of animal treatments. The study was designed to allow for 2 weeks of pretreatment with drug-containing diets, followed by simultaneous administration of drug-containing diets and 4-NQO for 8 weeks. After 1.5 weeks of 4-NQO, drug-containing diets were stopped, due to toxicity, and resumed for 8 weeks after completion of 4-NQO. At the end of the study, animals were euthanized and tongues harvested.

treatments and for 1.5 weeks during 4-NQO treatments. Administration of drug-containing diets was stopped at this point, due to unforeseen toxicity of combining 4-NQO with either erlotinib or guggulipid, and resumed after the 8 weeks of 4-NQO treatment. 4-NQO-containing water was prepared by thawing stock solutions, diluting to 12.5 mg/mL in propylene glycol and adding 2 mL to each bottle of 250 mL sterilized water (final concentration of 100 µg/mL). 4-NQO-containing water was made and changed once per week for 8 weeks. Four mice in each treatment group received the special diet but no 4-NQO in their water. Figure 1 describes the timeline of animal treatments.

Dissection, histology, and immunohistochemistry

Tongues of euthanized mice were harvested and fixed in 10% formalin. The ventral aspect of each tongue was inked and tongues cut in multiple horizontal sections. Tongues then underwent tissue processing and paraffin embedding. Blocks were sectioned completely and every tenth slide stained with hematoxylin & eosin (H&E). Each H&E-stained slide was examined by an investigator blinded to treatment groups. Identification of dysplastic and neoplastic lesions was supervised by a head and neck pathologist (R.S.) who reviewed 10% of cases. Mildly dysplastic and normal appearing tissues were grouped together and the rest categorized by moderate to severe dysplasia and squamous cell carcinoma. Each mouse was categorized by the highest grade lesion identified.

Unstained slides from adjacent levels to those in which lesions were identified were used for IHC studies. Because of small numbers of lesions in the erlotinib group, all dysplastic and neoplastic lesions were stained from this group and a representative subset, with the same proportion of dysplasia versus neoplasia to the erlotinib group, were chosen from the vehicle- and guggulipid-treated groups. Sections were stained with an antibody specific for STAT3 (Cell Signaling Technology). Scoring was performed by an investigator who was blinded to treatment group. Immunohistochemical score = (% of tumor scored as 1+) × 1 + (% of tumor scored as 2+) × 2 + (% of tumor scored as 3+) × 3.

Results

Toxicity of combining 4-NQO and erlotinib or guggulipid

To maximize exposure to erlotinib and guggulipid and attempt primary prevention of oral carcinogenesis, mice were treated with drug-supplemented diets for 2 weeks prior to 4-NQO administration. Continued administration of the special diets was intended but precluded by unexpected toxicity occurring with the combination of drug-containing diets and 4-NQO. After 1.5 weeks of 4-NQO treatment combined with the special diets, 28 of 80 mice in the erlotinib group and 5 of 80 mice in the guggulipid group died suddenly (Fig. 2A). The average weight of mice in both groups dropped (Fig. 2B). Deaths did not occur in the groups receiving either 4-NQO water alone (control diet) or the special diets without 4-NQO. The deaths, therefore, resulted from unforeseen toxicity of combining 4-NQO with either guggulipid or erlotinib. Drug-containing diets were promptly discontinued in mice receiving 4-NQO treatments and resumed after completion of the 8 weeks of 4-NQO treatment. Although the death rate slowed dramatically and average weight increased after withdrawal of the drug-containing diets, more mice died over the course of the experiment (Fig. 2A). Necropsy of one of the mice that died after combining 4-NQO with erlotinib indicated hemorrhagic gastroenteritis (data not shown).

Kinetics of lesion development in this model

Examination of mouse tongues at 5 weeks after completion of 4-NQO treatments demonstrated that 9 of 129 mice in the control group and 5 of 75 in the guggulipid group (~7% of each) had oral tumors that were visible on gross examination (Fig. 3A). No tumors were seen in the erlotinib group at this point. Beginning at 5 weeks after 4-NQO treatment, mice were sampled, weekly, from the control group and H&E-stained sections of their tongues examined for the presence of dysplastic and neoplastic lesions (Table 1). By 7 weeks post-4-NQO treatment, 10 of 10 mice had dysplastic or neoplastic lesions. The rationale for

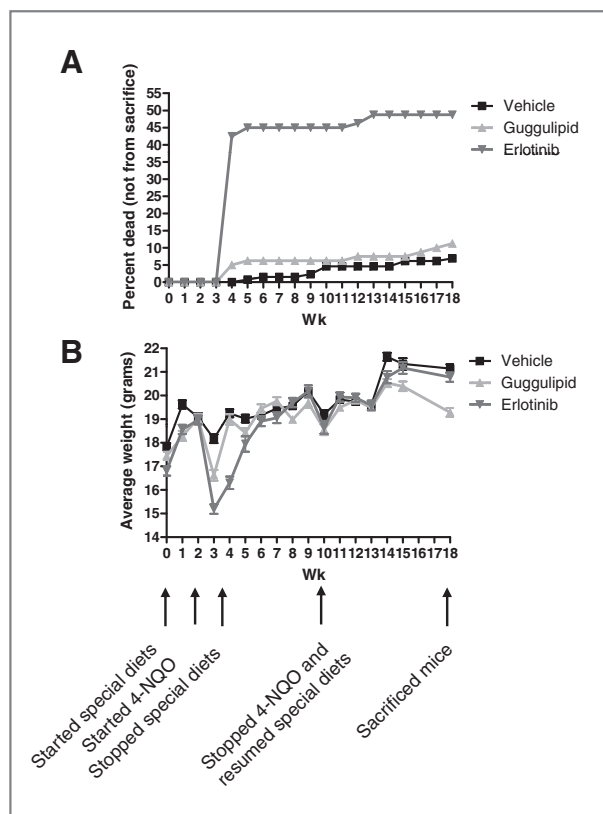


Figure 2. Toxicity of combining 4-NQO with drug-containing diets. A, percentages of mice that died, without being purposely sacrificed, during the study, are plotted. B, animals were weighed approximately once per week throughout the study.

this sampling was that when 10 of 10 mice had lesions, there was a probability of 0.89 that at least 80% of the remaining mice in the control group should have lesions as well. The remaining mice were sacrificed at 8 weeks post-4-NQO treatment.

Erlotinib, but not guggulipid, prevents progression beyond mild oral dysplasia in 4-NQO-treated mice.

Tongues harvested from the mice sacrificed at 8 weeks post-4-NQO treatment were paraffin embedded and sectioned completely onto glass slides. Every tenth slide was H&E stained and examined by an investigator who was blinded to treatment group.

The study was designed to compare the incidence of lesions, both preneoplastic and neoplastic versus numbers of normal appearing tongues occurring in each group. Each mouse was classified according to the highest grade lesion found on its tongue. During blinded histologic examination, however, it was clear that the vast majority of mice had at least mild dysplasia. It was decided, at this point, that mild dysplasia, a lesion that is not necessarily preneoplastic in humans, should be considered to be in the same category as normal appearing tongues in this model. Indeed, at the end of the study, it was discovered that the

only mice without at least mild dysplasia (i.e., completely normal) were the few (4 per group) treated with drug-containing diets but who never received 4-NQO. Figure 3A shows the gross appearance of representative tumors. The histologic appearances of representative lesions are shown in Figure 3B to E.

Figure 4 shows the incidence of dysplastic and neoplastic lesions in each group. 78.9% of the mice in the control group were found to have lesions that were higher grade than mild dysplasia, whereas only 24.4% of the erlotinib-treated group had such lesions, a 69% decrease overall ($P < 0.001$). 80.6% of the mice in the guggulipid-treated group had lesions that were higher grade than mild dysplasia. This very small increase over the incidence in the control group was not statistically significant.

The incidence of invasive SCC, specifically, did not necessarily fall into the same pattern. SCC was observed on tongues of 14.7% of mice in the control group, 12.19% in the erlotinib group, and 27.5% in the guggulipid group. This is explained, in part, by the very small numbers of mice with SCC (e.g., only 5 SCCs in the erlotinib group), making such a comparison unreliable. In addition, many of the SCCs were noted to be very small, only captured on 1 slide, for example. In general, moderate and severe dysplasia were also detected on tongues with SCC, further supporting the rationale for combining all lesions greater than mild dysplasia into the same category upon analysis.

Immunostaining of selected lesions

As inhibitors of the EGFR-STAT3 signaling axis were tested in this study, select tongues with an approximately even distribution of dysplasia and SCC in each group (total of 30 in the control group, 10 in the erlotinib group, and 20 in the guggulipid group) were stained, by IHC, with an antibody specific for STAT3. Again, because several lesions were very small, some of the lesions seen on H&E staining were not seen on immunostained slides, despite use of immediately adjacent sections in H&E and immunostaining. Numbers of stained SCCs, in the erlotinib group in particular, were very small ($n = 3$), such that IHC data comparing SCCs were unreliable and showed large variance. In comparing dysplastic lesions, on the other hand, mild decreases, that were not statistically significant, were seen in expression of STAT3 in both erlotinib and guggulipid treatment groups compared with vehicle (Fig. 5). The lack of statistical significance, again, may be due to the low numbers of dysplastic lesions in each group (vehicle: $n = 22$, erlotinib: $n = 7$, guggulipid: $n = 12$). In addition, the stain intensity did not vary greatly between sections, so that all sections, regardless of group, received scores between 70 and 180, despite a possible scoring range of 0 to 300, contributing to small quantitative differences between groups.

In addition to examining STAT3, we also stained these sections for pMAPK and pAKT, proteins also downstream of EGFR. However, no significant decrease in pMAPK or pAKT was seen in the erlotinib-treated group compared with controls, as examined by IHC. Nor did expression of

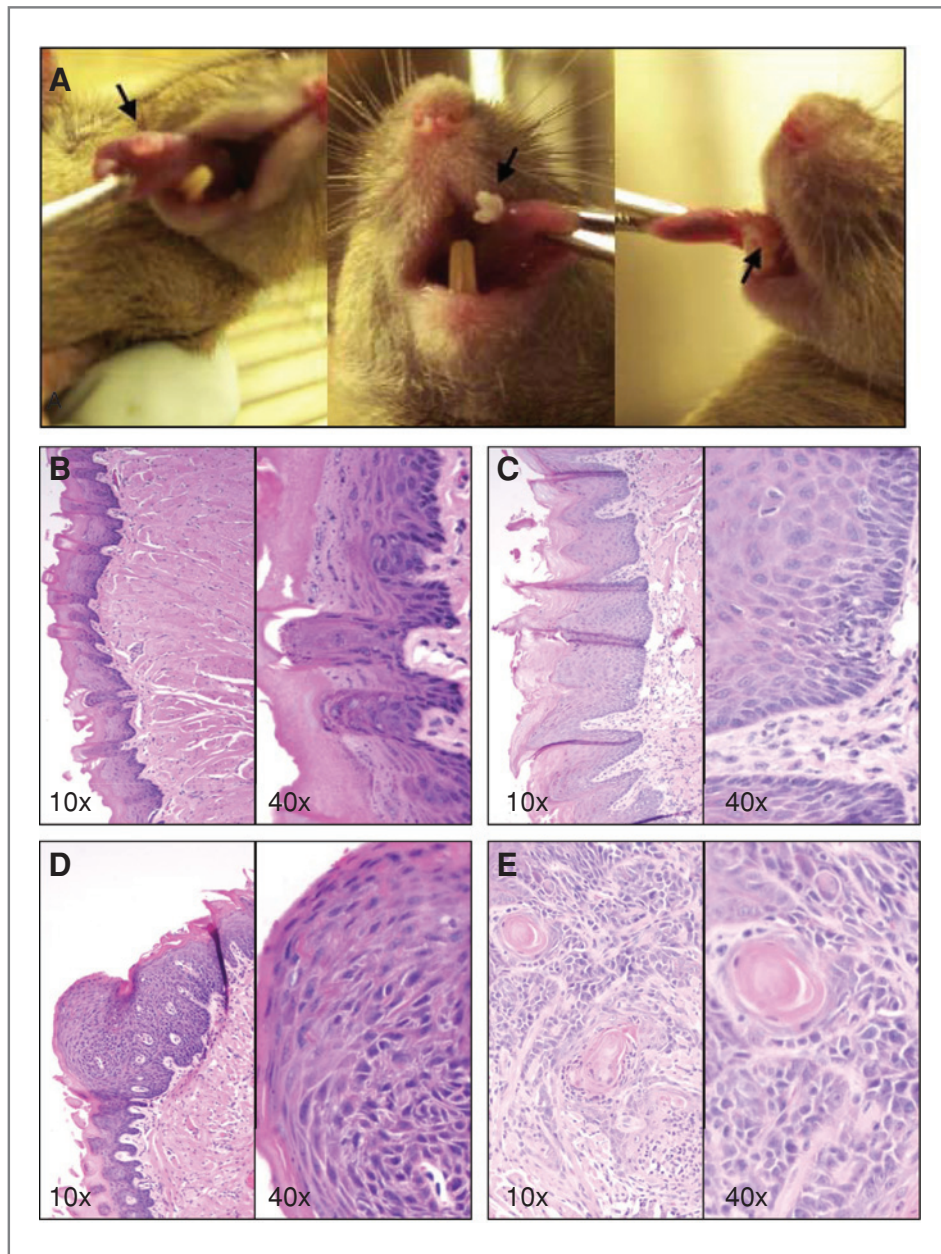


Figure 3. Gross and histologic appearance of 4-NQO-induced oral lesions. A, representative tumors from the control group, 7 weeks post-carcinogen treatment, on dorsal tongue (left), right lateral border (middle), and left lateral border (right). Arrows indicate tumors. Photomicrographs of normal tongue (B), 4-NQO-induced mild dysplasia (C), 4-NQO-induced moderate/severe dysplasia (D), and 4-NQO-induced squamous cell carcinoma (E).

Table 1. Incidence of dysplastic and neoplastic lesions in mice sampled from the control group

Weeks post-carcinogen treatment	Total number	Normal	Mild to severe dysplasia	Invasive SCC
5	4	1/4	3/4	0/4
6	9	0/9	9/9	0/9
7	10	0/10	9/10	1/10

these proteins trend significantly over time during carcinogenesis, as observed comparing levels in the tissue from control group mice sampled at 5, 6, and 7 weeks after 4-NQO treatment (data not shown).

Discussion

The current study examined guggulipid and erlotinib as potential chemopreventive therapies in HNSCC. Erlotinib has been shown to be an active agent in the treatment of HNSCC (30). Guggulipid has demonstrated anti-cancer activity in preclinical models of HNSCC (26). The

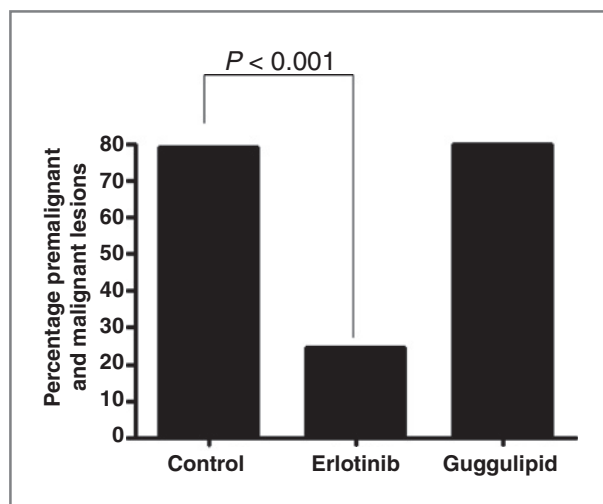


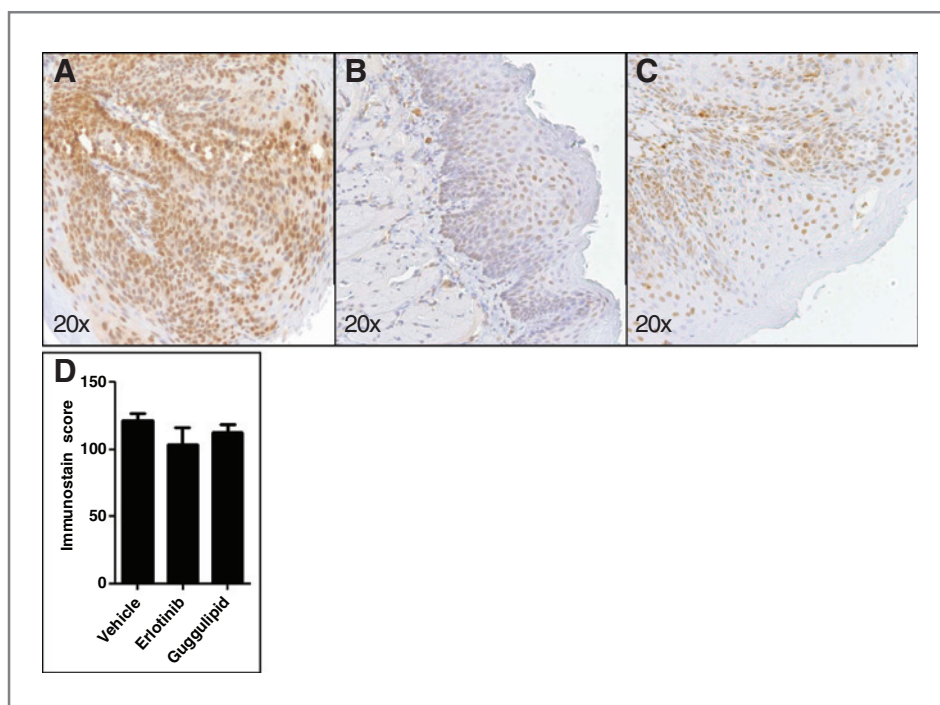
Figure 4. Incidence of premalignant and malignant lesions in control-, erlotinib-, and guggulipid-treated groups. H&E-stained sections of tongues harvested from mice in each group were examined for the presence of premalignant (moderate and high-grade dysplasia) plus malignant lesions. The group treated with erlotinib demonstrated a decrease in numbers of such lesions ($P < 0.001$).

4-NQO-induced model of oral carcinogenesis provides us with the opportunity to examine the chemopreventive activities of these agents. Erlotinib was found to significantly inhibit progression from mild dysplasia to premalignant and malignant lesions, with rates of these lesions decreasing by 69% compared with the control group. Guggulipid, on the other hand, did not inhibit oral carcinogenesis in this model.

The 4-NQO-induced mouse model of oral SCC has been used to investigate the chemopreventive properties of several agents (14, 15, 28, 29). As 4-NQO induces the formation of DNA adducts and eventually dysplastic and neoplastic lesions that histologically and molecularly resemble those seen in human head and neck carcinogenesis (28, 29), it was thought that this model would be appropriate for use in testing potential chemopreventive agents. Whether or not results seen in this model are translatable, in terms of identifying chemopreventive therapies that will be effective in humans, has yet to be determined in clinical trials. Ongoing studies investigating erlotinib's chemopreventive activity in humans may contribute information about the translatability of results found in using the 4-NQO model (19, 20).

In the current study, erlotinib and guggulipid were administered in animal diets. This method of administration has been employed in various studies investigating potential chemopreventive agents and has also been used, previously, to deliver guggulipid, showing effects on markers of guggulipid's cholesterol lowering and antidiabetic activities (31, 32). The observed inhibition of carcinogenesis with the erlotinib-containing diet and the fact that, when administered simultaneously with 4-NQO, both drug-containing diets conferred increased toxicity over the carcinogen alone, confirms that each drug was delivered in the diets. Indeed, compared with oral gavage, which bypasses much of the oral cavity, administering each drug in the diet may have allowed for better exposure to the animals' oral mucosa. In addition, daily oral gavage over the extended duration of this study was not permitted by the Institutional Animal Care and Use Committee (IACUC), as it would have

Figure 5. STAT3 levels in 4-NQO-induced dysplasia. Photomicrographs of the dysplastic lesions with the median immunostaining score for each group, occurring in tongues of animals from the vehicle-treated (A), erlotinib-treated (B), and guggulipid-treated (C) groups stained for STAT3. D, graphical description of immunostaining scores for each group ($P = 0.11$ for vehicle vs. erlotinib and $P = 0.41$ for vehicle vs. guggulipid).



resulted in considerable oral and pharyngeal irritation in the animals, presenting a safety hazard. The dose of erlotinib added to the diet was based on that found to be tolerated, in the long term, in unpublished studies (Dr. Ronald Lubet, NIH, personal communication). The dose of guggulipid chosen was based on that found to have anticancer and STAT3-inhibiting activity in a xenograft model of HNSCC (26) and also based on HPLC data, from Sabinsa Corporation, describing the concentration of guggulsterone in guggulipid. In the current study, administration of drug-containing diets was started prior to the carcinogen to maximize delivery of each potential chemopreventive agent and attempt to determine their maximal chemopreventive activity *in vivo*. This method does not resemble the time-frame for potential human usage of a chemopreventive therapy. The translational potential of future studies may be enhanced by administering the preventive agent after the initiation of carcinogenesis. For similar reasons, the study was terminated at a time point when most of the animals in the control group had premalignant, rather than malignant lesions, to avoid waiting until most animals in control and treatment groups had carcinoma, potentially obscuring a small chemopreventive effect.

The EGFR-STAT3 signaling axis is known to play a key role in growth and survival of HNSCC (33). Expression of EGFR has been used to predict progression from premalignant lesions to oral SCC (17). Furthermore, levels of EGFR are elevated in the 4-NQO-induced model, similar to human HNSCC (29). This led us to hypothesize that both erlotinib, which inhibits EGFR and guggulipid, containing guggulsterone, which inhibits STAT3, a molecule downstream of EGFR, would prevent oral carcinogenesis in this model.

The study did demonstrate the chemopreventive activity of erlotinib. In this group, 69% fewer mice developed malignant or premalignant lesions compared with vehicle. Only modest decreases, that were not statistically significant, in the molecular target of interest, STAT3, were seen with administration of erlotinib. The combination of successful inhibition of the formation of SCCs with erlotinib treatment and loss of mice due to the toxicity of combining erlotinib and 4-NQO unfortunately resulted in low numbers of lesions available for staining in the erlotinib-treated group and little power to detect a difference in STAT3 expression. There was also a low degree of overall variability in stain intensity, leading to small differences in immunostaining scores between groups.

The mice that received erlotinib or guggulipid alone, in the absence of carcinogen, did not experience any toxicity, in both this study (4 mice per group) and in a previous study testing the drug-containing diets on 5 mice per group (data not shown). These specific conditions, involving coadministration of 4-NQO, which on its own is known to be toxic, should not be used to extrapolate information about erlotinib's or guggulipid's toxicity in humans. Erlotinib has already been used in clinical trials and is known to have certain side effects, most notably skin toxicity (34). It is possible that skin toxicity may be acceptable in patients already at high risk for HNSCC SPT, for example, or that

lower, less-toxic, doses may be sufficient for chemopreventive therapy.

Guggulipid, which is a safe and inexpensive natural product, was nevertheless shown to be ineffective in inhibiting oral carcinogenesis in this particular model. Erlotinib is certainly a more specific and perhaps a more effective and/or bioavailable compound, at the doses administered, than guggulipid. This is supported by the far greater toxicity of combining erlotinib with 4-NQO (Fig. 2A and B) and by erlotinib's association with side effects in humans compared with guggulipid's relative safety. Guggulipid is a plant extract, with multiple components, including guggulsterone, which itself is known to have multiple potential molecular targets. Guggulsterone's many possible molecular targets include those downstream from various nuclear receptors, such as the farnesoid x receptor, progesterone receptor, estrogen receptor- α , and pregnane x receptor, to which it binds (35). Effects on these targets may counteract the anticancer activity seen with guggulsterone-mediated STAT3 inhibition seen *in vitro* (25). Because guggulipid did not inhibit carcinogenesis in this study and because of the aforementioned limitations in detecting changes in STAT3, only the relative increased toxicity in guggulipid plus 4-NQO over 4-NQO alone provides evidence of guggulipid delivery. It is quite possible that a higher dose or different method of administering guggulipid would have had a greater effect on STAT3. Prior studies utilizing the xenograft model of HNSCC demonstrated a decrease in STAT3 induced by the same dosage of guggulipid used in the current study, however (25).

The current study justifies targeting the EGFR as a strategy for chemoprevention of HNSCC. Indeed, various clinical studies investigating this potential use for EGFR inhibitors are currently underway (19–21). Erlotinib's known toxicity presents a challenge in terms of determining appropriate doses for long-term administration in patients who are at risk for HNSCC but do not currently have HNSCC. If erlotinib is found to have chemopreventive activity in humans, it will, however, represent an important therapeutic opportunity for patients who, either due to exposure history, premalignant lesion, or a prior diagnosis of HNSCC, are at high risk for this frequently fatal malignancy for which there is currently no approved preventive therapy.

Disclosure of Potential Conflicts of Interest

No potential conflicts of interest were disclosed.

Grant Support

This project is supported by grants from the NIH: 1F30 ES015669 to R.J. Leeman-Neill and P50 CA097190 and an American Cancer Society Clinical Research Professorship to J.R. Grandis.

The costs of publication of this article were defrayed in part by the payment of page charges. This article must therefore be hereby marked *advertisement* in accordance with 18 U.S.C. Section 1734 solely to indicate this fact.

Received September 20, 2010; revised November 5, 2010; accepted December 9, 2010; published OnlineFirst December 16, 2010.

References

- Sturgis EM. A review of social and behavioral efforts at oral cancer preventions in India. *Head Neck* 2004;26:937-44.
- Day GL, Blot WJ. Second primary tumors in patients with oral cancer. *Cancer* 1992;70:14-9.
- Slaughter DP, Southwick HW, Smejkal W. Field cancerization in oral stratified squamous epithelium: clinical implications of multicentric origin. *Cancer* 1953;6:963-8.
- Wolbach SB, Howe PR. Nutrition classics. The Journal of Experimental Medicine 42:753-77, 1925. Tissue changes following deprivation of fat-soluble A vitamin. S. Burt Wolbach and Percy R. Howe. *Nutr Rev* 1978;36:16-9.
- Hong WK, Endicott J, Itri LM, Doos W, Batsakis JG, Bell R, et al. 13-cis-retinoic acid in the treatment of oral leukoplakia. *N Engl J Med* 1986;315:1501-5.
- Hong WK, Lippman SM, Itri LM, Karp DD, Lee JS, Byers RM, et al. Prevention of second primary tumors with isotretinoin in squamous-cell carcinoma of the head and neck. *N Engl J Med* 1990;323:795-801.
- Khuri FR, Lee JJ, Lippman SM, Kim ES, Cooper JS, Benner SE, et al. Randomized phase III trial of low-dose isotretinoin for prevention of second primary tumors in stage I and II head and neck cancer patients. *J Natl Cancer Inst* 2006;98:441-50.
- Lippman SM, Lee JJ, Karp DD, Vokes EE, Benner SE, Goodman GE, et al. Randomized phase III intergroup trial of isotretinoin to prevent second primary tumors in stage I non-small-cell lung cancer. *J Natl Cancer Inst* 2001;93:605-18.
- Kim JW, Amin AR, Shin DM. Chemoprevention of head and neck cancer with green tea polyphenols. *Cancer Prev Res* 2010;3:900-9.
- Pisters KM, Newman RA, Coldman B, Shin DM, Khuri FR, Hong WK, et al. Phase I trial of oral green tea extract in adult patients with solid tumors. *J Clin Oncol* 2001;19:1830-8.
- Schwartz JL, Baker V, Larios E, Chung FL. Molecular and cellular effects of green tea on oral cells of smokers: a pilot study. *Mol Nutr Food Res* 2005;49:43-51.
- Armstrong WB, Kennedy AR, Wan XS, Taylor TH, Nguyen QA, Jensen J, et al. Clinical modulation of oral leukoplakia and protease activity by Bowman-Birk inhibitor concentrate in a phase IIa chemoprevention trial. *Clin Cancer Res* 2000;6:4684-91.
- Khuri FR, Shin DM. Head and neck cancer chemoprevention gets a shot in the arm. *J Clin Oncol* 2008;26:345-7.
- Czeminski R, Amorphimoltham P, Patel V, Molinolo AA, Gutkind JS. Targeting mammalian target of rapamycin by rapamycin prevents tumor progression in an oral-specific chemical carcinogenesis model. *Cancer Prev Res* 2009;2:27-36.
- Hasina R, Martin LE, Kasza K, Jones CL, Jalil A, Lingen MW. ABT-510 is an effective chemopreventive agent in the mouse 4-nitroquinoline 1-oxide model of oral carcinogenesis. *Cancer Prev Res* 2009;2:385-93.
- Grandis JR, Tweardy DJ. Elevated levels of transforming growth factor alpha and epidermal growth factor receptor messenger RNA are early markers of carcinogenesis in head and neck cancer. *Cancer Res* 1993;53:3579-84.
- Taoudi Benchekroun M, Saintigny P, Thomas SM, El-Naggar AK, Papadimitrakopoulou V, Ren H, et al. Epidermal growth factor receptor expression and gene copy number in the risk of oral cancer. *Cancer Prev Res* 2010;3:800-9.
- Ohashi K, Takigawa N, Osawa M, Ichihara E, Takeda H, Kubo T, et al. Chemopreventive effects of gefitinib on nonsmoking-related lung tumorigenesis in activating epidermal growth factor receptor transgenic mice. *Cancer Res* 2009;69:7088-95.
- Saba N, Muller S, Chen AY, Grist W, Gibson K, Nannapaneni S, Yang CS, Khuri FR, Chen ZG, Shin DM. Chemoprevention with erlotinib and celecoxib in advanced premalignant lesions of the head and neck: results of a phase I study. *J Clin Oncol* 2010 ASCO Annu Meeting Proc 2010;28:5535.
- Anderson M.D. Cancer Center. Erlotinib prevention of oral cancer. In: ClinicalTrials.gov [Internet] Bethesda (MD): National Library of Medicine (US)2000-[cited 2011 Sept 11] Available from: <http://www.clinicaltrials.gov/show/NCT00402779>NLM identifier: NCT00402779.
- Sidney Kimmel Cancer Center. Cetuximab in Treating Patients With Precancerous Lesions of the Upper Aerodigestive Tract. In: ClinicalTrials.gov [Internet] Bethesda (MD): National Library of Medicine (US) 2000-[cited 2011 Sept 11] Available from: <http://www.clinicaltrials.gov/show/NCT00524017> NLM identifier: NCT00524017.
- Leeman RJ, Lui VW, Grandis JR. STAT3 as a therapeutic target in head and neck cancer. *Expert Opin Biol Ther* 2006;6:231-41.
- Grandis JR, Drenning SD, Zeng Q, Watkins SC, Melhem MF, Endo S, et al. Constitutive activation of Stat3 signaling abrogates apoptosis in squamous cell carcinogenesis *in vivo*. *Proc Natl Acad Sci USA* 2000;97:4227-32.
- Urizar NL, Moore DD. GUGULIPID: a natural cholesterol-lowering agent. *Annu Rev Nutr* 2003;23:303-13.
- Shishodia S, Harikumar KB, Dass S, Ramawat KG, Aggarwal BB. The guggul for chronic diseases: ancient medicine, modern targets. *Anticancer Res* 2008;28:3647-64.
- Leeman-Neill RJ, Wheeler SE, Singh SV, Thomas SM, Seethala RR, Neill DB, et al. Guggulsterone enhances head and neck cancer therapies via inhibition of signal transducer and activator of transcription-3. *Carcinogenesis* 2009;30:1848-56.
- Agarwal RC, Singh SP, Saran RK, Das SK, Sinha N, Asthana OP, et al. Clinical trial of guggulipid—a new hypolipidemic agent of plant origin in primary hyperlipidemia. *Indian J Med Res* 1986;84:626-34.
- Hawkins BL, Heniford BW, Ackermann DM, Leonberger M, Martinez SA, Hendler FJ. 4NQO carcinogenesis: a mouse model of oral cavity squamous cell carcinoma. *Head Neck* 1994;16:424-32.
- Tang XH, Knudsen B, Bemis D, Tickoo S, Gudas LJ. Oral cavity and esophageal carcinogenesis modeled in carcinogen-treated mice. *Clin Cancer Res* 2004;10:301-13.
- Thomas SM, Grandis JR. Pharmacokinetic and pharmacodynamic properties of EGFR inhibitors under clinical investigation. *Cancer Treat Rev* 2004;30:255-68.
- Cornick CL, Strongitharm BH, Sassano G, Rawlins C, Mayes AE, Joseph AN, et al. Identification of a novel agonist of peroxisome proliferator-activated receptors alpha and gamma that may contribute to the anti-diabetic activity of guggulipid in Lep(ob)/Lep(ob) mice. *J Nutr Biochem* 2009;20:806-15.
- Cui J, Huang L, Zhao A, Lew JL, Yu J, Sahoo S, et al. Guggulsterone is a farnesoid X receptor antagonist in coactivator association assays but acts to enhance transcription of bile salt export pump. *J Biol Chem* 2003;278:10214-20.
- Grandis JR, Drenning SD, Chakraborty A, Zhou MY, Zeng Q, Pitt AS, et al. Requirement of Stat3 but not Stat1 activation for epidermal growth factor receptor-mediated cell growth *in vitro*. *J Clin Invest* 1998;102:1385-92.
- Li T, Perez-Soler R. Skin toxicities associated with epidermal growth factor receptor inhibitors. *Target Oncol* 2009;4:107-19.
- Brobst DE, Ding X, Creech KL, Goodwin B, Kelley B, Staudinger JL. Guggulsterone activates multiple nuclear receptors and induces CYP3A gene expression through the pregnane X receptor. *J Pharmacol Exp Ther* 2004;310:528-35.

Cancer Prevention Research

Inhibition of EGFR-STAT3 Signaling with Erlotinib Prevents Carcinogenesis in a Chemically-Induced Mouse Model of Oral Squamous Cell Carcinoma

Rebecca J. Leeman-Neill, Raja R. Seethala, Shivendra V. Singh, et al.

Cancer Prev Res 2011;4:230-237. Published OnlineFirst December 16, 2010.

Updated version Access the most recent version of this article at:
doi:[10.1158/1940-6207.CAPR-10-0249](https://doi.org/10.1158/1940-6207.CAPR-10-0249)

Cited articles This article cites 33 articles, 14 of which you can access for free at:
<http://cancerpreventionresearch.aacrjournals.org/content/4/2/230.full#ref-list-1>

Citing articles This article has been cited by 6 HighWire-hosted articles. Access the articles at:
<http://cancerpreventionresearch.aacrjournals.org/content/4/2/230.full#related-urls>

E-mail alerts [Sign up to receive free email-alerts](#) related to this article or journal.

Reprints and Subscriptions To order reprints of this article or to subscribe to the journal, contact the AACR Publications Department at pubs@aacr.org.

Permissions To request permission to re-use all or part of this article, use this link
<http://cancerpreventionresearch.aacrjournals.org/content/4/2/230>.
Click on "Request Permissions" which will take you to the Copyright Clearance Center's (CCC) Rightslink site.